

Collaborative Learning



Sri Adichunchanagiri Shikshana Trust
BGS Global Institute of Medical Sciences & Hospital
 (Affiliated to Rajiv Gandhi University of Health Sciences Bangalore)
 # 67, BGS Health & Education City, Uttarahalli Main Road, Kengeri,
 Bangalore - 560 060, Karnataka, (INDIA)

Phone 080 - 65653007
 Website: www.bgsghs.edu.in
 Email: principal@bgsghs@gmail.com
 Email: surgery@bgsghs@gmail.com

DEPARTMENT OF SURGERY

Letter No: BGS-GIMS/SURC/ 2021/012 **Date:- 05/03/2021.**
CIRCULAR

TUMOR BOARD MEET MARCH 2021

Venue:- Department PG Seminar Hall 010
Time:- 17th March 2021, 02:15PM

IP No	Patient's Name	Age (Yrs)	Sex	Diagnosis
21022262	Mrs. Chikhalakanna	65	F	Carcinoma Rectum
21030171	Mr. Thimma Nayak	54	M	Carcinoma Oesophagus

ASSOCIATE PROFESSOR
Dr. Lokesh M N **Dr. Madan M**
 Dept. of General Surgery Department of Surgery
 BGS GIMS & Hospital, Dattahalli, Bangalore-560067
 Associate Professor Head of Department
 I/C Tumour Board

Copy to :- HOD Pathology/HOD Radiology/Department Notice Board
 Samples to be checked for slides & history

Name: Chikhalakanna	Age/Sex: 65 Yrs/Female	IP/OP No: 2102262
Date: 02/03/2021	Dept: Surgery I	Ref Dr.: Dr. Madan
HISTOPATHOLOGIC REPORT		

CLINICAL DIAGNOSIS: ? Carcinoma rectum
SPECIMEN: Biopsy from the rectal growth
GROSS: Received multiple (7) grey white tiny tissue bits altogether measuring 1 x 1 cm.

MICROSCOPY: Multiple sections studied from all embedded tissue show fragments of rectal mucosa with focal dysplasia. In the overlying epithelium, A malignant infiltrating tumor composed of cells arranged in irregularly distributed tubular and glandular structures are noted. Mucin depletion noted. Tumor cells show moderate anisonucleosis, coarse clumped chromatin, irregular nuclear membrane and prominent nucleoli. Mitosis is increased - 3-4 / HPF. Atypical mitosis present. Intervening stroma is desmoplastic and shows mixed inflammatory infiltrate composed of lymphocytes, neutrophils and plasma cells.

IMPRESSION: FEATURES ARE SUGGESTIVE OF WELL DIFFERENTIATED ADENOCARCINOMA - BIOPSY FROM RECTUM.

NOTE: Correlate with colonoscopy findings.

CASE 2

NAME - Thimma Nayak
AGE - 54 years / M
GROSS : Received 2 mucosal bits mounted on paper.

MICROSCOPY : Section studied shows fragment of tumour tissue exhibiting features of moderately differentiated squamous cell carcinoma. Stroma shows dense mixed inflammatory infiltrate composed of lymphocytes, plasma cells and neutrophils.

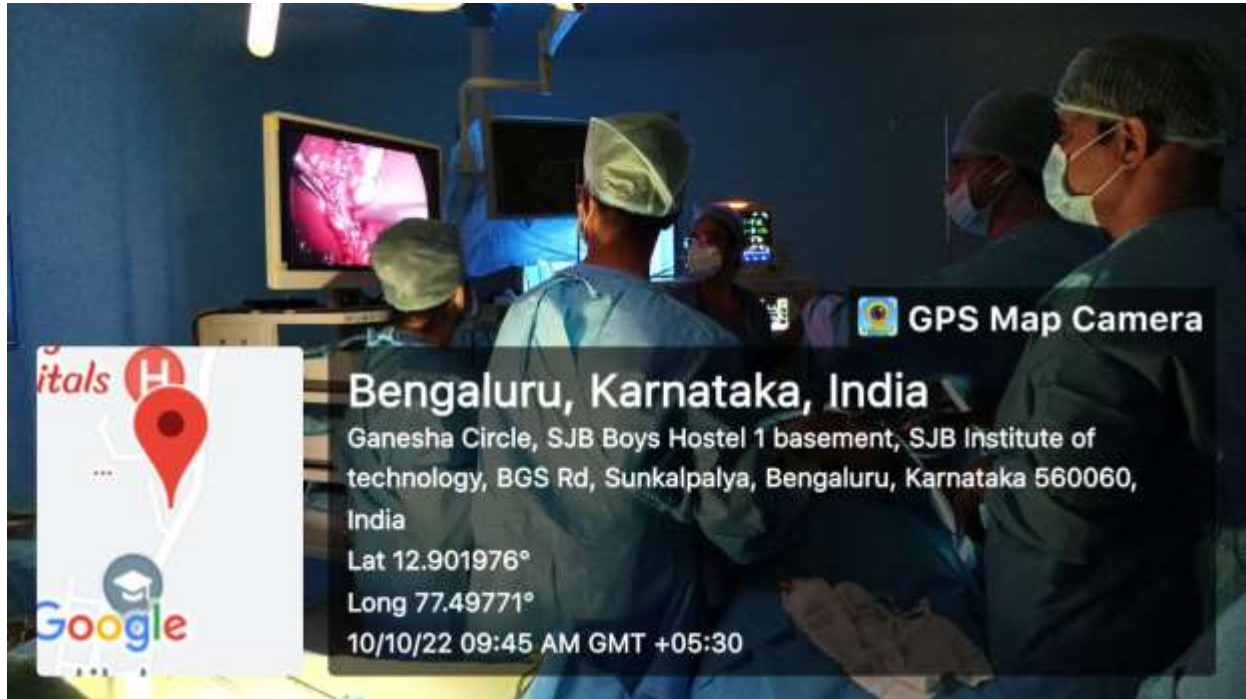IMPRESSION: Moderately differentiated squamous cell carcinoma

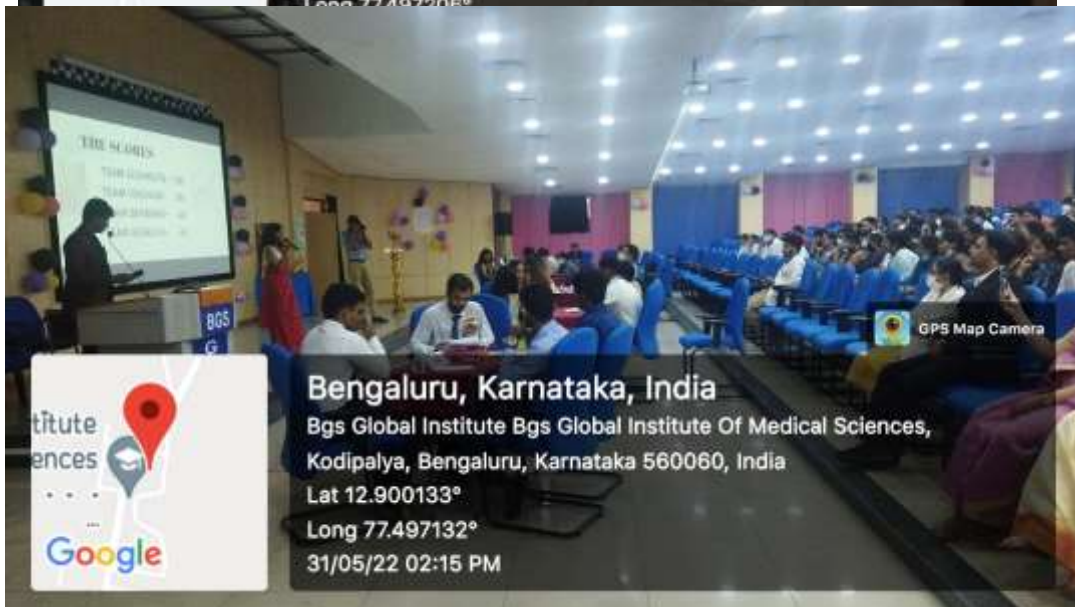




Interdepartmental Meeting

Cooperative Learning





Problem Based Learning



Cooperative learning



Cooperative Learning in Camps



Case Based learning



Child Examination




Case Based learnin



Case based Learning in Camps

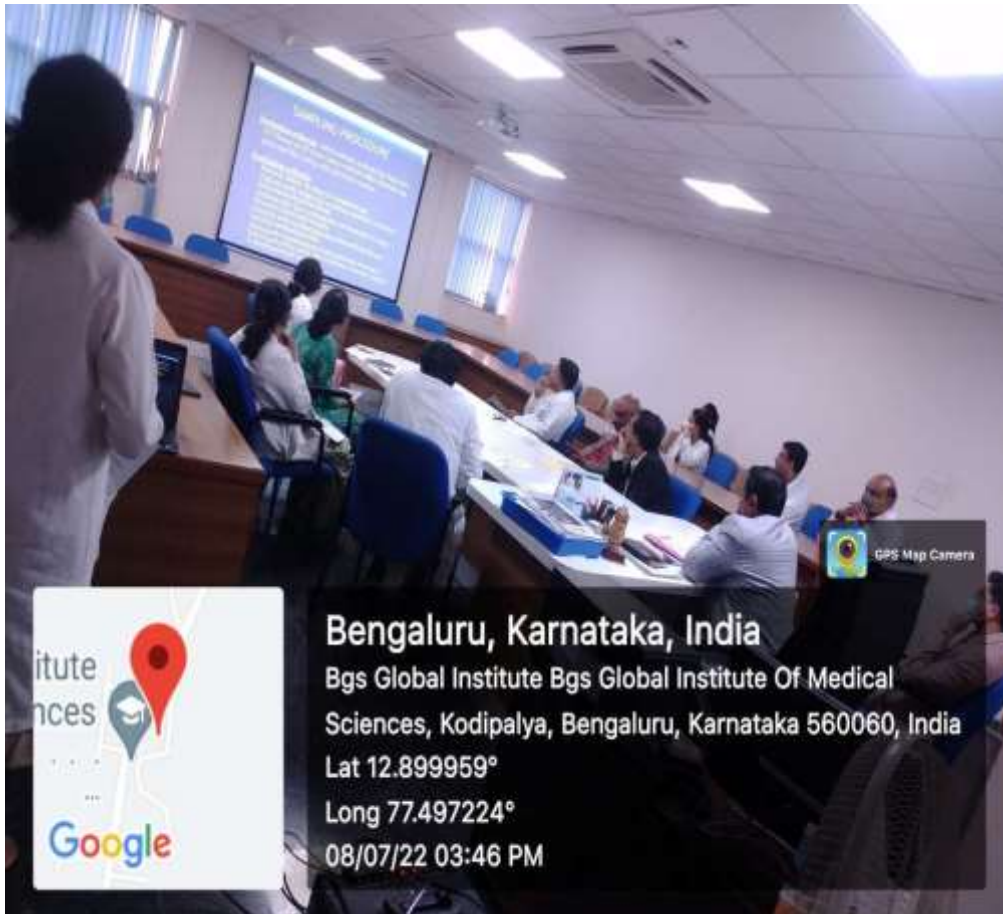

Case Based Learning

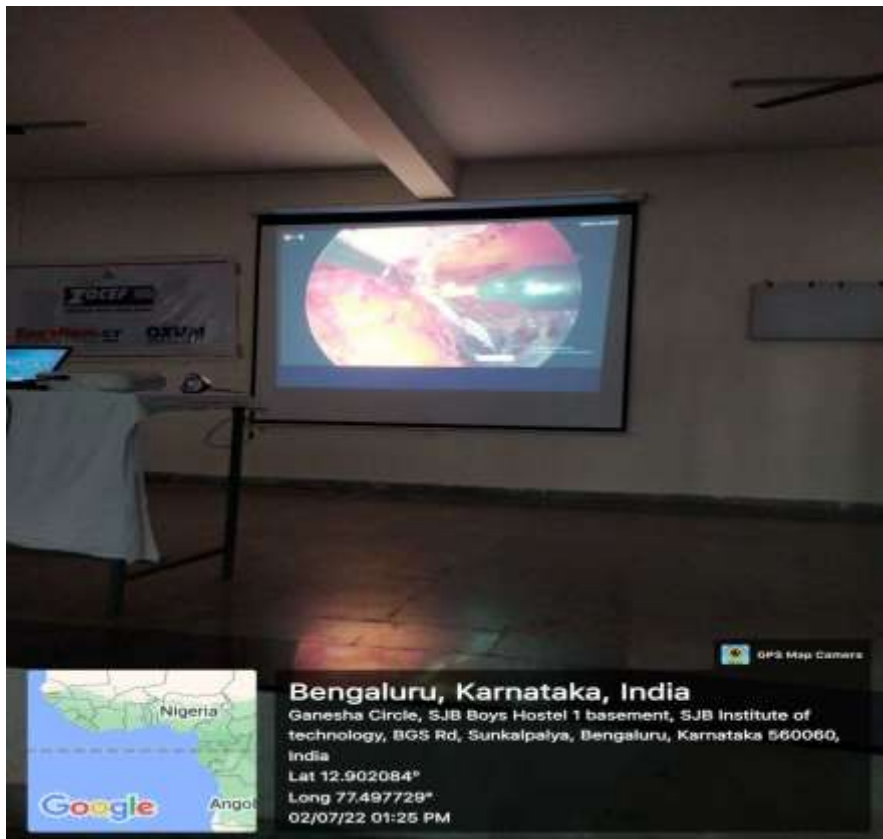

Case Based Learning


Project Based Learning



Participative Learning



Live Operation



Bengaluru, Karnataka, India

Ganesh Circle, SJB Boys Hostel 1 basement, SJB Institute of technology, BGS Rd, Sunkalpalya, Bengaluru, Karnataka 560060, India

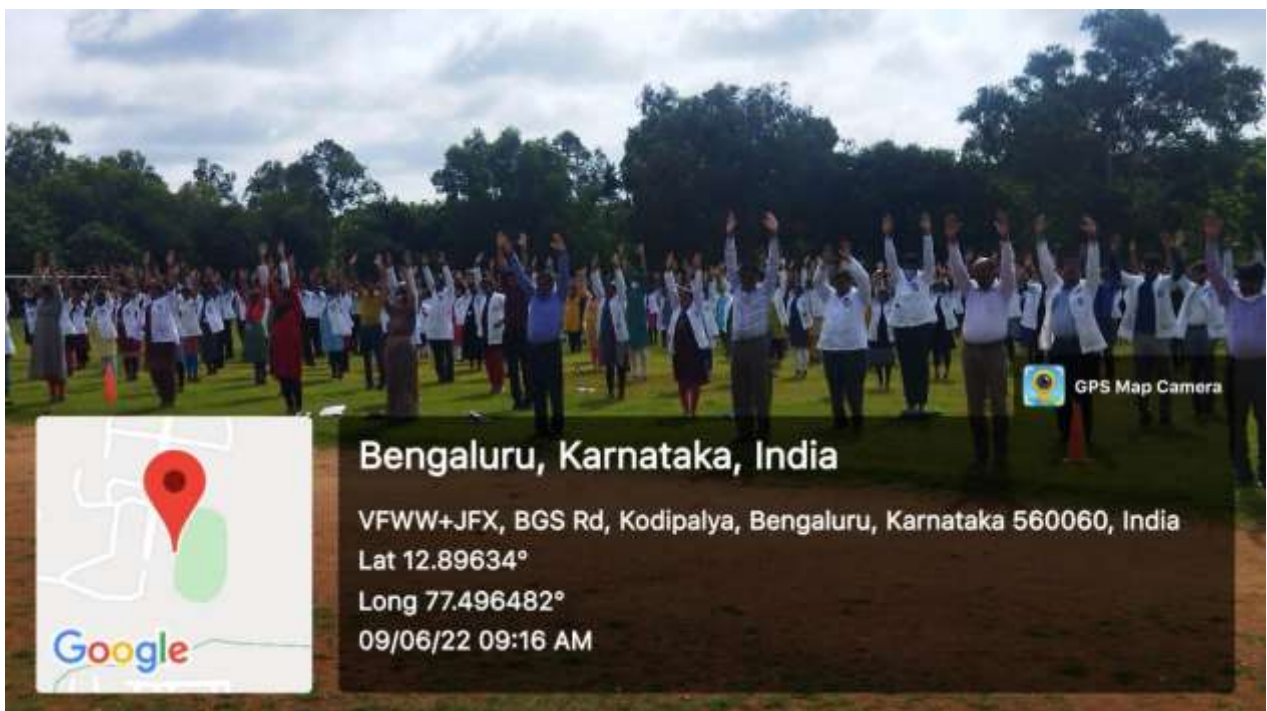Lat 12.902084°

Long 77.497729°

02/07/22 10:25 AM



Live Video of Operation



Yoga Practice Session

Self-Directed Learning / Flip Class Room

11/1/22, 10:58 AM

Educator Login | Medwhiz LMS



MEDWHIZ



- Subject
- CBME
- Lecture Files
- Live class
- Attendance
- Assessment
- Groups
- Announcement
- Forum
- Log Book
- Class Room
- Help

Competency Name :

AN11.1 Describe and demonstrate muscle groups of upper arm with emphasis on biceps and triceps brachii

Back

Upload

Filter

2

Clear Filter

Teaching Learning Method

Subjective Assessment

Lecture

- Bedside Clinic
- Group Discussion
- DOAP
- Skill Lab
- Practical

Back

By the end of the
• Compartment
• Muscles
• Clinical releva

Compartment

- Divided into anterior and posterior compartments
- By extending called medial intramuscular

Anterior Compartment

- Muscles of anterior compartment
1. Coracobrachialis
 2. Biceps brachii
- Brachialis

Coracobrachialis

- Origin
- Tip of process of coracoid process of scapula
- Insertion
- Middle of medial border of humerus

Role Play



Poster Presentation

Mona
DEAN cum PRINCIPAL
Dean cum Principal
BGS Global Institute of Medical Sciences
67, Uttarahalli Road, Kengeri,
Bengaluru - 560 060.